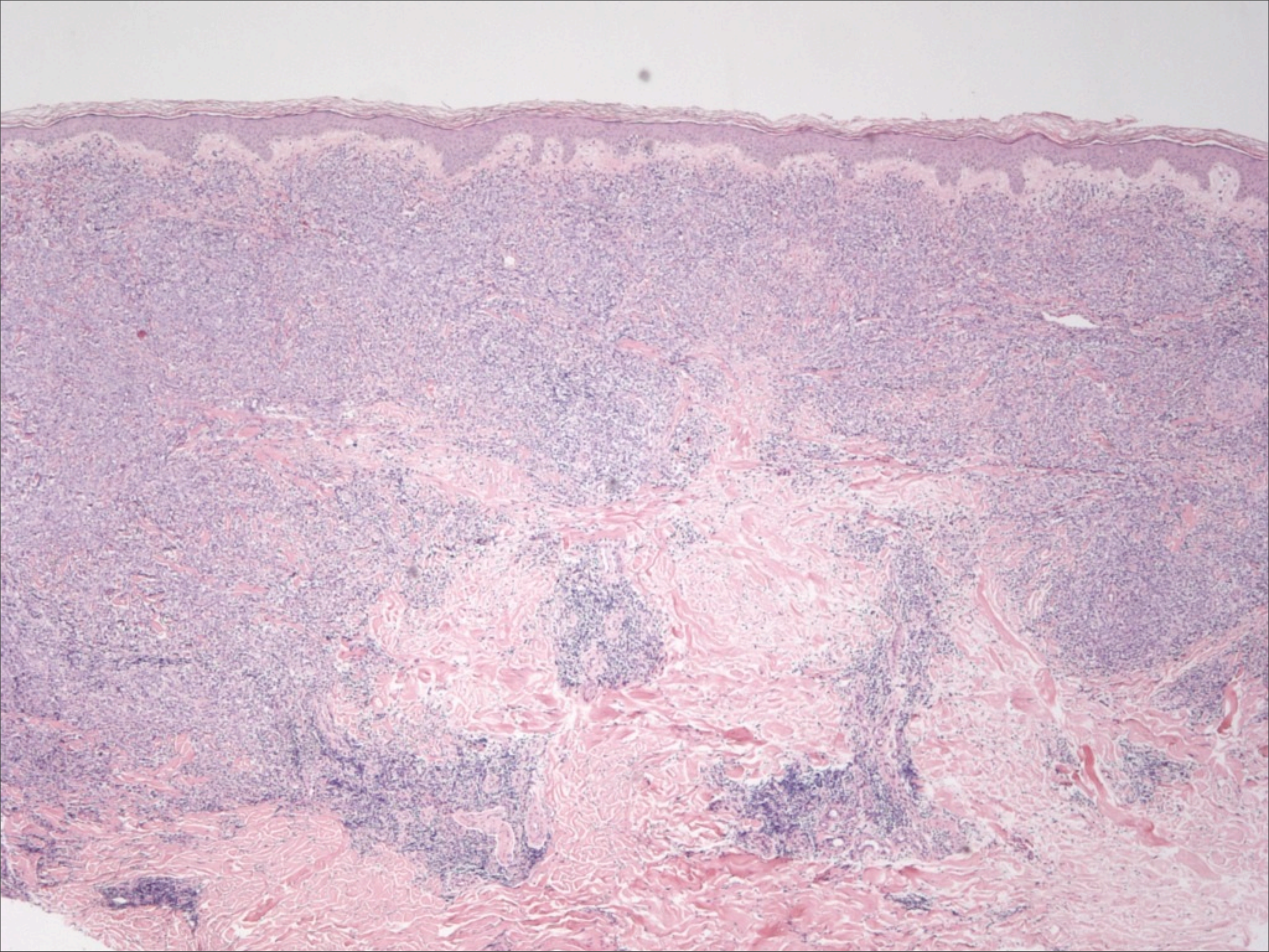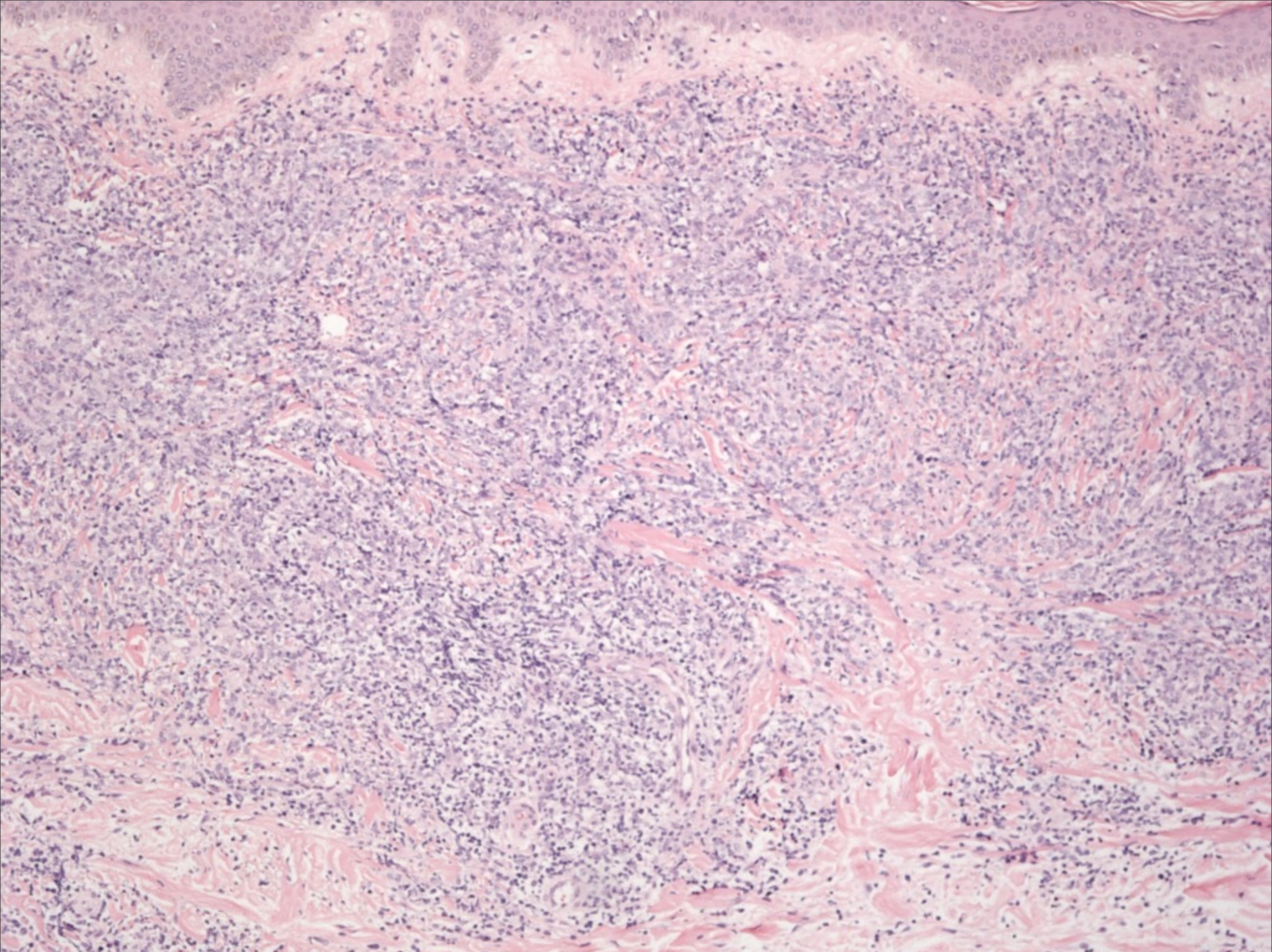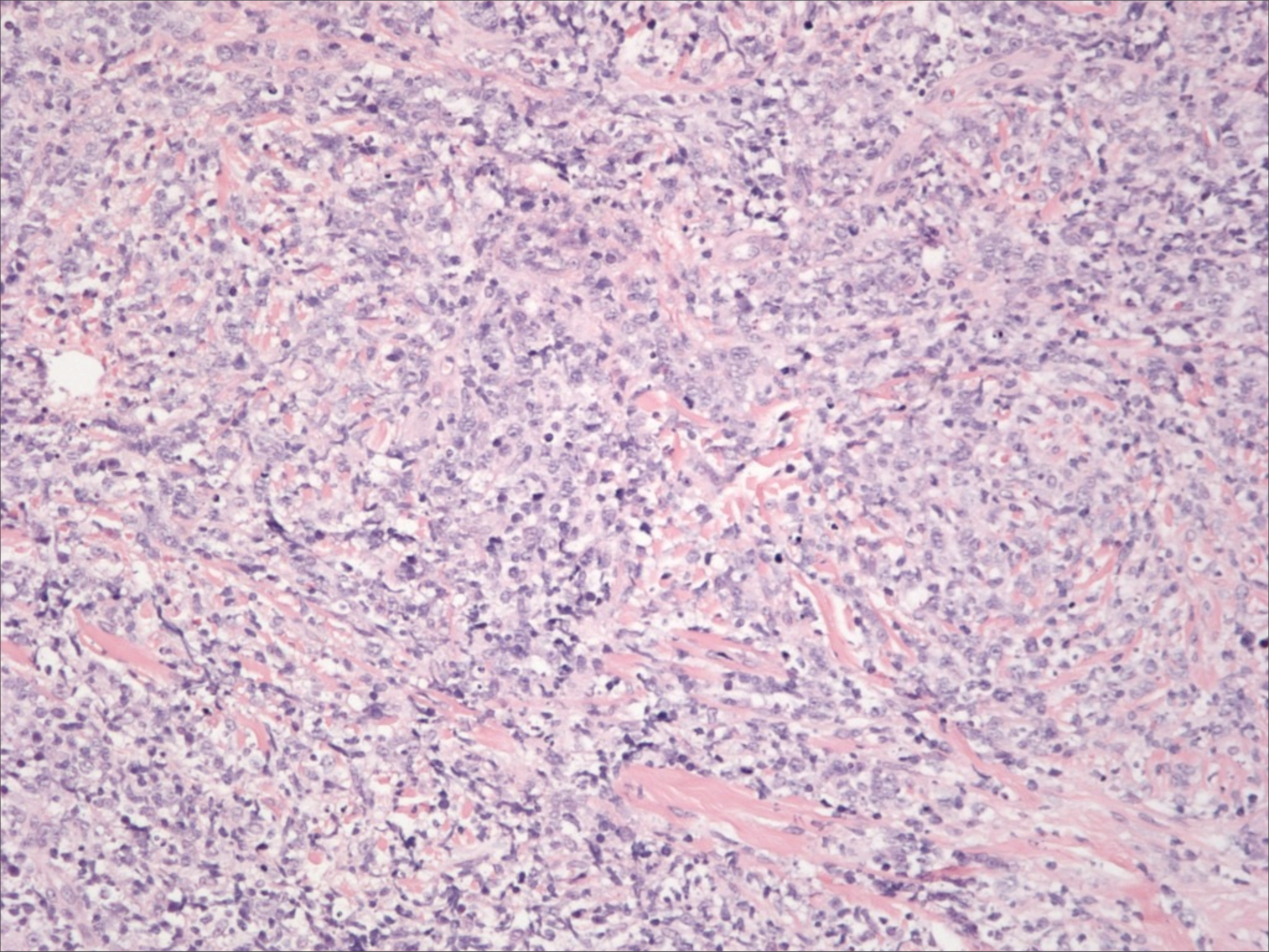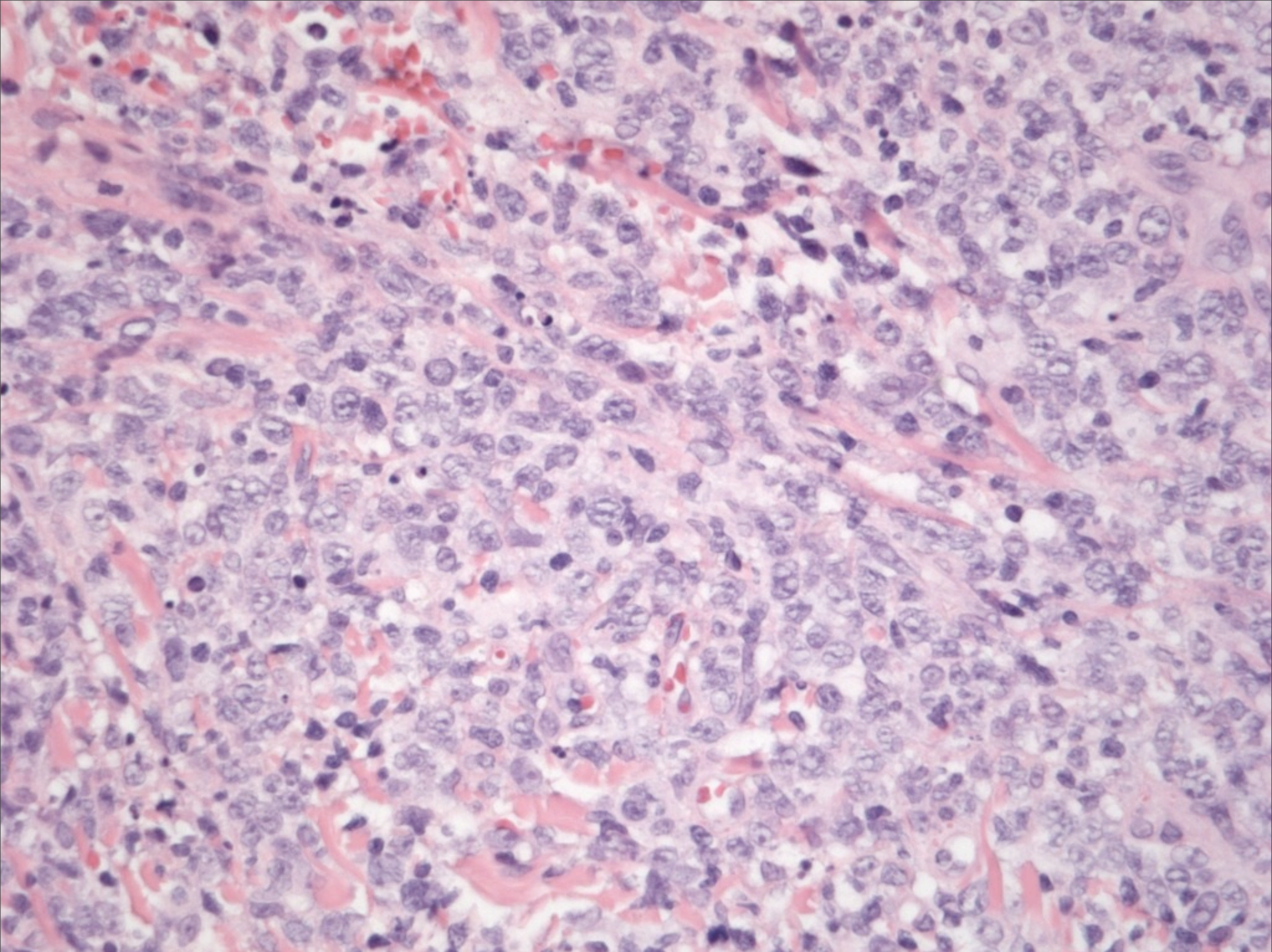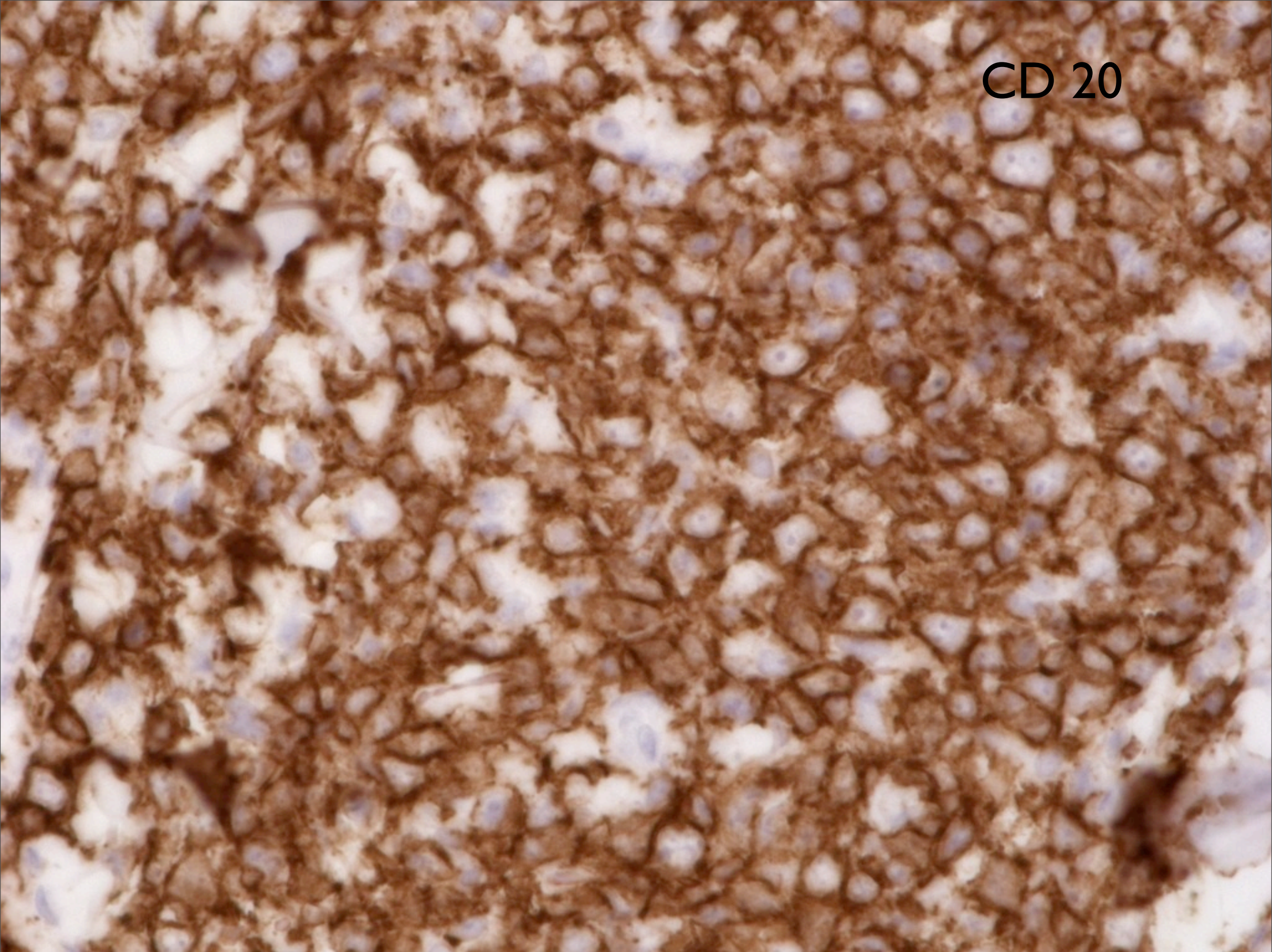
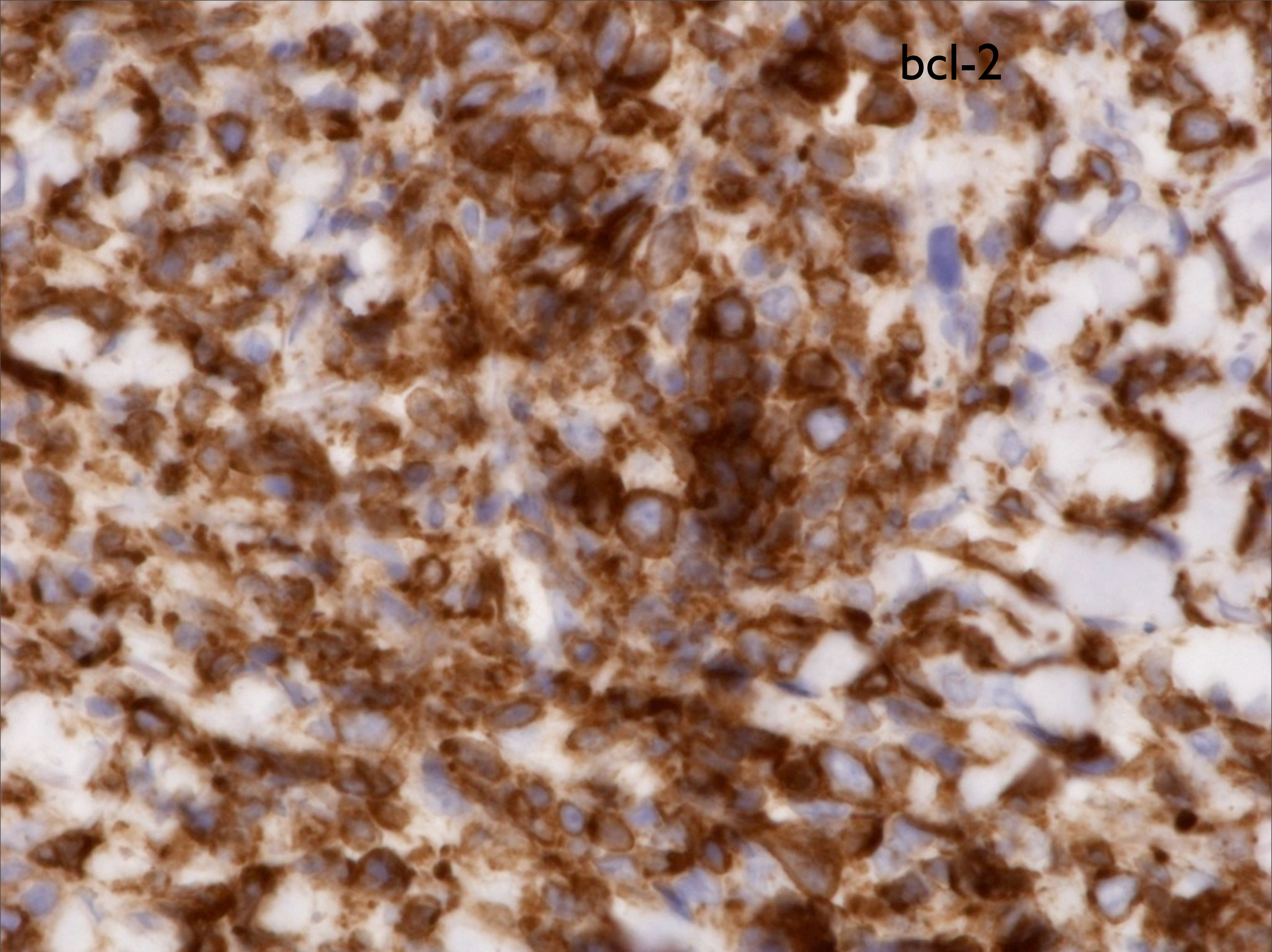


CD 20

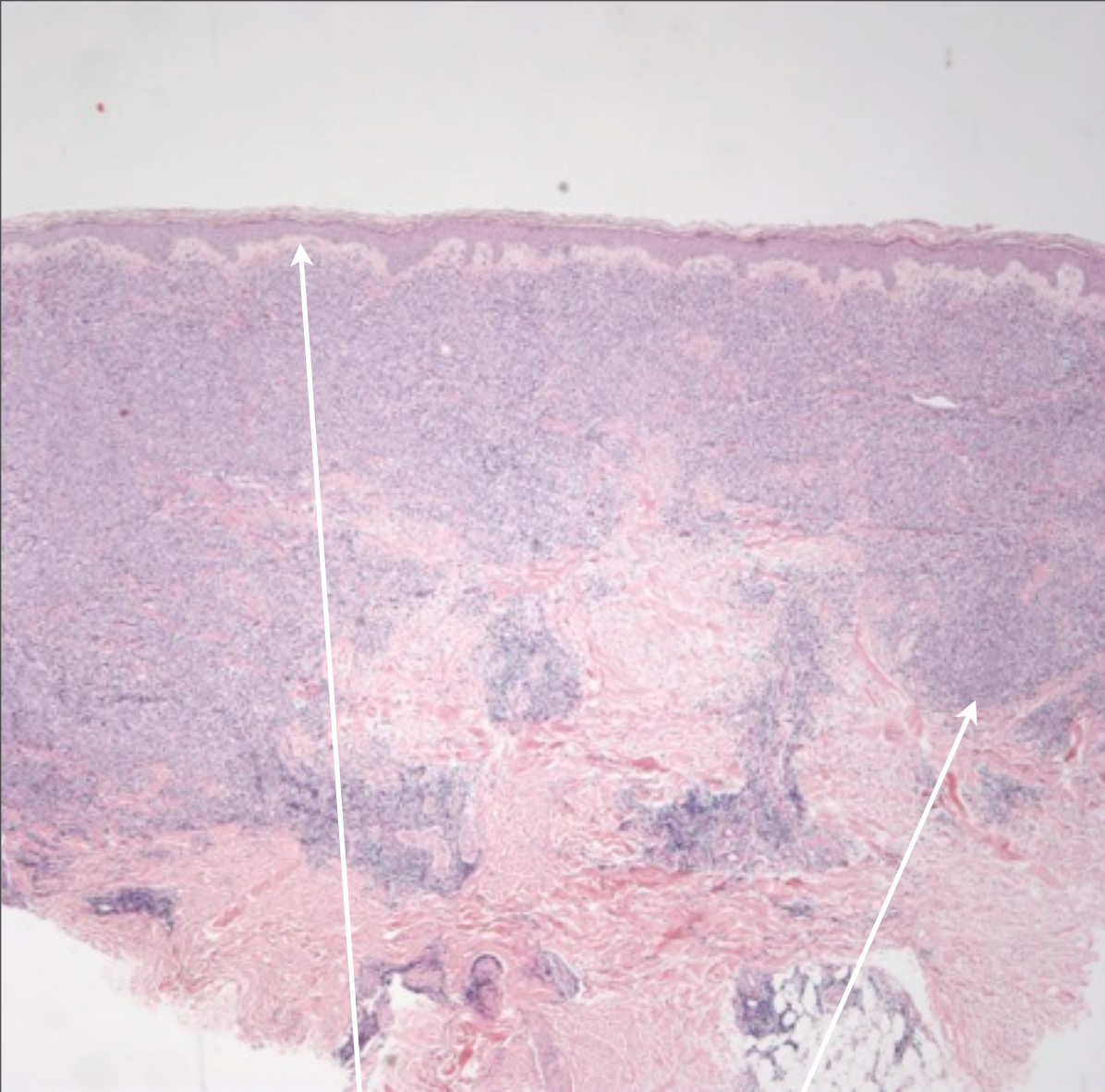


bcl-2



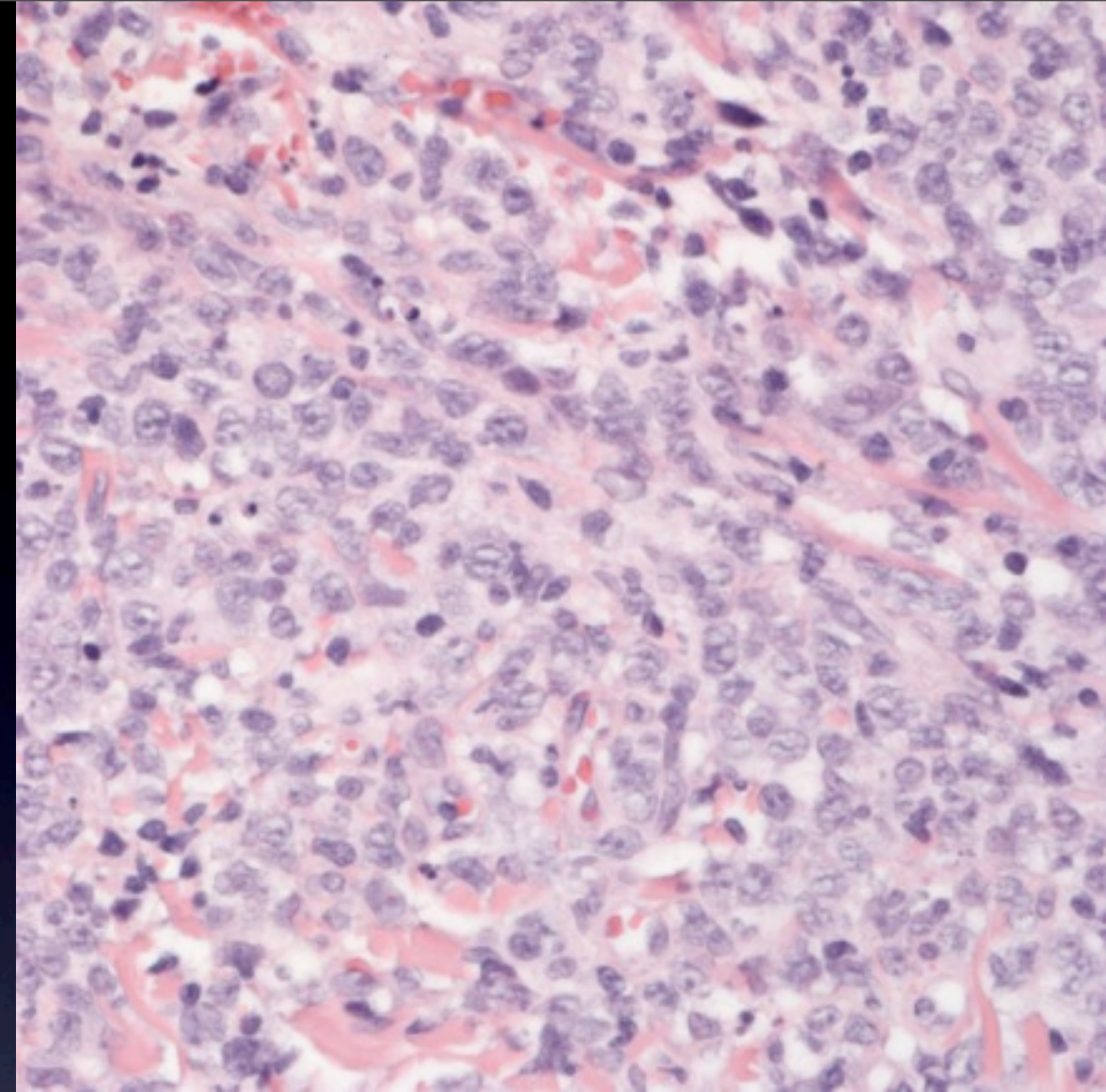
MUMI

Diffuse Large B-Cell Lymphoma, Leg Type



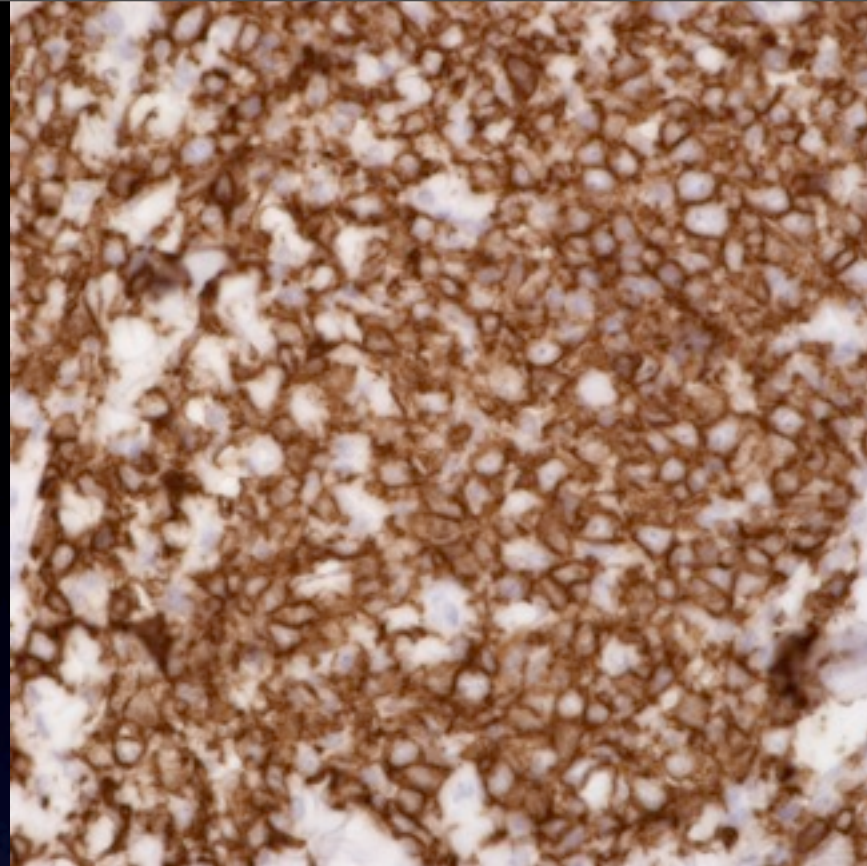
Grenz zone

Diffuse infiltrate



Large cells >50%

MUM I



CD 20

bcl-2

